



**PATIENT**

Snowflake Cargill

**SPECIES**

Feline

**BREED**

DSH

**SEX**

MN

**AGE**

9 years

**WEIGHT**

10 #

**INTERPRETED BY**

Remo Lobetti, BVSc,  
MMedVet (Med),  
PhD, Dipl. ECVIM

**IMAGING  
PERFORMED BY**

Lara Wiseman, DVM

**HOSPITAL NAME**

Boca Midtowne  
Animal Hospital

**REFERRING VET**

**INVOICE**

302704

**DATE**

1/21/22

**PRESENTING CLINICAL SIGNS**

History: Grade II heart murmur, weight loss, poor appetite. Incompletely resected soft tissue sarcoma 9/2021 in the axillary region.

Physical Examination: N/A.

Urinalysis: Pending.

CBC: Pending.

Serum Biochemistry: Abnormal fPL, rest pending.

Radiographic Findings: N/A.

**ULTRASONOGRAPHIC EXAMINATION OF THE ABDOMEN**

**Urinary System**

Full urinary bladder with a normal appearance and thickness of the wall. Moderate amount of floating hyperechogenic sediment. No uroliths evident.

Normal trigone area, proximal urethra (0.3 cm), and iliac blood vessels.

Normal iliac lymph nodes. Ureters not visualized.

Normal renal size (both 4 cm) with increased echogenic appearance, some loss of cortico-medullary differentiation, and normal pelvis and capsule.

**Reproductive System**

N/A.

**Adrenal Glands**

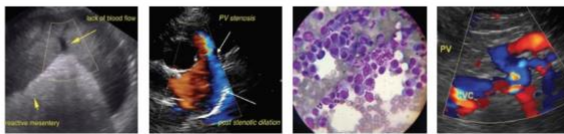
Normal shape, echogenic appearance, size, and position. Left 0.43 cm, right 0.37 cm.

**Spleen**

Normal size (0.7 cm) and echogenic appearance. Smooth homogenous parenchyma, smooth curvi-linear capsule, and normal vasculature. No evidence of inflammatory, neoplastic, infarction, or infiltrative changes noted.

**Liver**

Normal size, echogenic appearance, and portal markings. No nodules or masses evident. Small gall bladder containing normal anechoic bile. Normal thickness and echogenic appearance of the gall bladder wall. Normal bile duct (0.24 cm).



**PATIENT**

Snowflake Cargill

**SPECIES**

Feline

**BREED**

DSH

**SEX**

MN

**AGE**

9 years

**WEIGHT**

10 #

**INTERPRETED BY**

Remo Lobetti, BVSc,  
MMedVet (Med),  
PhD, Dipl. ECVIM

**IMAGING  
PERFORMED BY**

Lara Wiseman, DVM

**HOSPITAL NAME**

Boca Midtowne  
Animal Hospital

**REFERRING VET**

**INVOICE**

302704

**DATE**

1/21/22

***Gastrointestinal***

Normal appearance of the gastro-esophageal junction, stomach, ileo-cecal junction, and colon with no loss of layering, normal wall thickness (stomach 0.24 cm) and peristalsis, and no distension of the lumen. Thickening of the duodenum (0.38 cm) and small intestine (0.37 cm) with a prominent hypoechoic appearance of the submucosal layer but with no loss of layering or distension of the lumen.

***Pancreas***

Normal size (right 0.8 cm) with a diffuse hypoechoic appearance. Regular capsule. Hyperechoic appearance of the mesentery and fat surrounding the pancreas.

***Free Abdomen***

No mesenteric lymphadenomegaly.  
No ascites.

**ULTRASONOGRAPHIC FINDINGS**

Primary findings:

- Enteropathy.
- Pancreatitis.

Secondary findings:

- Urinary bladder sediment.
- Age-related renal changes.

**INTERPRETATION OF THE FINDINGS & FURTHER RECOMMENDATIONS**

Etiologies for the enteropathy would be inflammatory bowel disease, parasitic enteritis, and dietary hypersensitivity, with emerging lymphoma a less likely differential diagnosis.

The appearance of the pancreas is consistent with pancreatitis.

Etiologies for the urinary bladder would be bacterial cystitis, sterile cystitis, crystalluria, hemorrhage.

Further assessment needs to be based on the pending results but could include fecal analysis, 3-view thoracic radiographs, quantitative fPL/PSL assay, serum cobalamin, and endoscopy of the upper GI tract with biopsies.

Specific therapy would be dependent on an etiological diagnosis.



**PATIENT**

Snowflake Cargill

**SPECIES**

Feline

**BREED**

DSH

**SEX**

MN

**AGE**

9 years

**WEIGHT**

10 #

**INTERPRETED BY**

Remo Lobetti, BVSc,  
 MMedVet (Med),  
 PhD, Dipl. ECVIM

**IMAGING PERFORMED BY**

Lara Wiseman, DVM

**HOSPITAL NAME**

Boca Midtowne  
 Animal Hospital

**REFERRING VET**

**INVOICE**

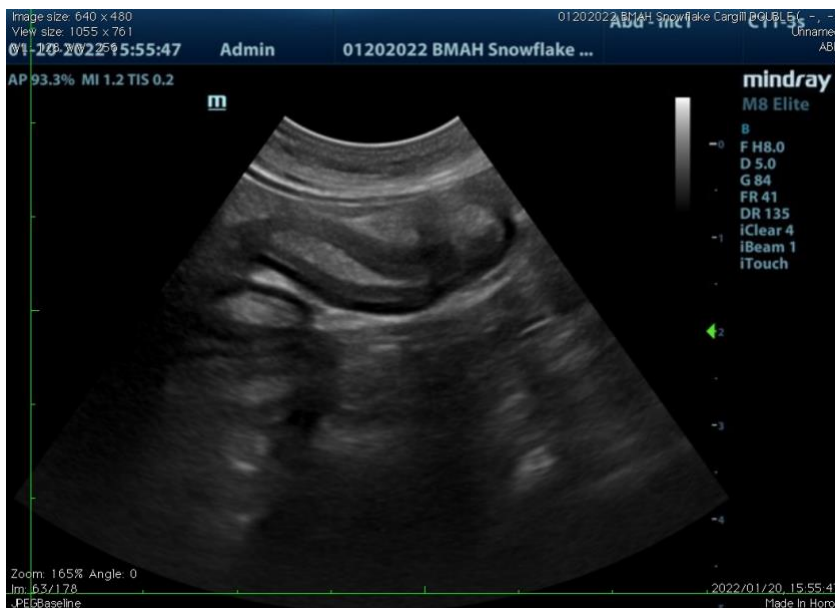302704

**DATE**

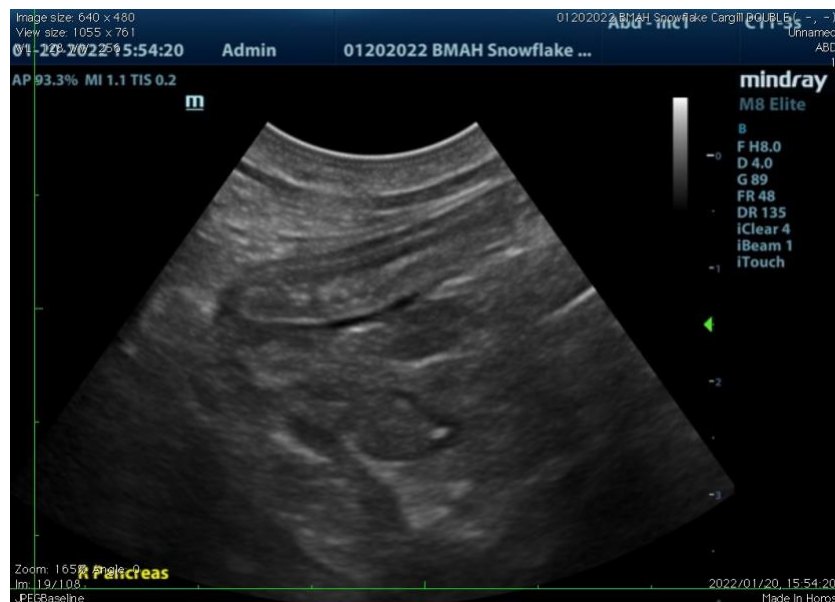1/21/22

**IMAGES**

**Small intestine**



**Pancreas**





**PATIENT**

**Kidney**

Snowflake Cargill

**SPECIES**

Feline

**BREED**

DSH

**SEX**

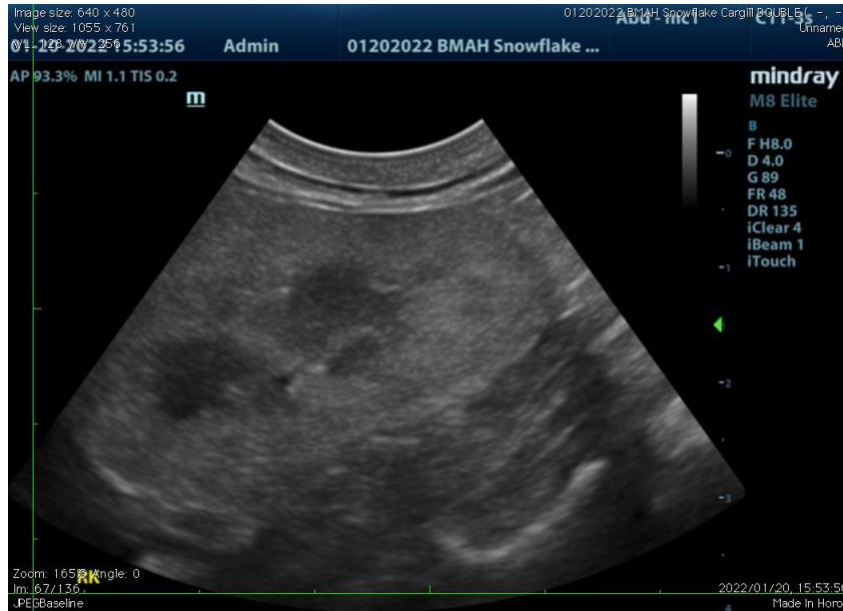MN

**AGE**

9 years

**WEIGHT**

10 #



**INTERPRETED BY**

Remo Lobetti, BVSc,  
MMedVet (Med),  
PhD, Dipl. ECVIM

**The information and recommendations provided are based on the images presented by the referring veterinarian. No evaluation can be communicated regarding pathology that was not visible in the image/video clips provided.**

**IMAGING PERFORMED BY**

Lara Wiseman, DVM

Thank you for this referral. If the clinical or image interpretation does not parallel your findings or if I can be of any further assistance please contact me.

**Remo Lobetti, BVSc, MMedVet (Med), PhD, Dipl. ECVIM (Internal Medicine)**  
rlobetti@mweb.co.za

**HOSPITAL NAME**

Boca Midtowne  
Animal Hospital

**REFERRING VET**

**INVOICE**

302704

**DATE**

1/21/22